




# ERS statement on chest imaging in acute respiratory failure

Davide Chiumello<sup>1,2</sup>, Giuseppe Francesco Sferrazza Papa<sup>3</sup>, Antonio Artigas<sup>4,5</sup>, Belaid Bouhemad<sup>6</sup>, Aleksandar Grgic<sup>7</sup>, Leo Heunks<sup>8</sup>, Klaus Markstaller<sup>9</sup>, Giulia M. Pellegrino<sup>2,3</sup>, Lara Pisani<sup>10</sup>, David Rigau<sup>11</sup>, Marcus J. Schultz<sup>12</sup>, Giovanni Sotgiu <sup>13</sup>, Peter Spieth<sup>14,15</sup>, Maurizio Zompatori<sup>16</sup> and Paolo Navalesi<sup>17</sup>

 @ERSpublications

**A variety of chest imaging techniques are now available for assessing patients with acute respiratory failure. This statement highlights characteristics, clinical indications and limitations of each technique as a guide for patient management.** <http://bit.ly/2XxYod7>

**Cite this article as:** Chiumello D, Sferrazza Papa GF, Artigas A, *et al.* ERS statement on chest imaging in acute respiratory failure. *Eur Respir J* 2019; 54: 1900435 [<https://doi.org/10.1183/13993003.00435-2019>].

**ABSTRACT** Chest imaging in patients with acute respiratory failure plays an important role in diagnosing, monitoring and assessing the underlying disease. The available modalities range from plain chest X-ray to computed tomography, lung ultrasound, electrical impedance tomography and positron emission tomography. Surprisingly, there are presently no clear-cut recommendations for critical care physicians regarding indications for and limitations of these different techniques.

The purpose of the present European Respiratory Society (ERS) statement is to provide physicians with a comprehensive clinical review of chest imaging techniques for the assessment of patients with acute respiratory failure, based on the scientific evidence as identified by systematic searches. For each of these imaging techniques, the panel evaluated the following items: possible indications, technical aspects, qualitative and quantitative analysis of lung morphology and the potential interplay with mechanical ventilation. A systematic search of the literature was performed from inception to September 2018. A first search provided 1833 references. After evaluating the full text and discussion among the committee, 135 references were used to prepare the current statement.

These chest imaging techniques allow a better assessment and understanding of the pathogenesis and pathophysiology of patients with acute respiratory failure, but have different indications and can provide additional information to each other.

---

This statement was endorsed by the ERS Executive Committee on June 7, 2019.

Received: 01 March 2019 | Accepted after revision: 16 May 2019

This article has supplementary material available from [erj.ersjournals.com](http://erj.ersjournals.com)

Copyright ©ERS 2019

## Introduction

Patients with acute respiratory failure require one or several imaging studies of the chest to diagnose underlying diseases, assess progression and evaluate treatment efficacy. Until a few decades ago, chest imaging of the critically ill consisted solely of chest X-ray (CXR). Additional imaging techniques have become widely available for the critically ill, including chest computed tomography (CT) and, more recently, positron emission tomography (PET) and bedside techniques such as lung ultrasound (LU) and electrical impedance tomography (EIT). Surprisingly, there are presently no clear recommendations for critical care physicians regarding indications for and limitations of these five imaging techniques.

To date, the limited use of chest magnetic resonance imaging (MRI) in pulmonary diseases is due to the physical properties of the pulmonary parenchyma and the long scan time. Although recent technical advances (*i.e.* parallel imaging, multi-array phase coils and ultra-short echo-time techniques enabling higher image quality and shorter scan time) have provided more detailed information on lung ventilation, inflammation, perfusion and structure, currently MRI is not used in the management of patients with acute respiratory failure. For these reasons, MRI was not included by the current task force.

The purpose of this European Respiratory Society (ERS) statement is to provide physicians with a comprehensive clinical review of chest imaging techniques for the assessment of patients with acute respiratory failure, based on the scientific evidence, as identified by systematic searches. Of the five imaging techniques selected by the Task Force Chairs, three are applicable at the bedside (CXR, LU, EIT) and two (CT and PET) require transfer to the radiological department.

For each of the included imaging techniques, the panel evaluated the following items: indications, technical aspects, qualitative and quantitative analysis of lung morphology and interaction with mechanical ventilation.

## Methods

The ERS Scientific Committee approved the development of a document on imaging techniques in acute respiratory failure by a task force (TF-2016-01) on May 2016 aimed at summarising the relevant literature. The task force was composed of several experts and chaired by D. Chiumello and P. Navalesi. All members disclosed potential conflicts of interest according to ERS policies.

## Search

A systematic search of the literature on the five imaging techniques (CXR, LU, CT, PET and EIT) was performed from inception to September 2018 on Medline/PubMed (National Library of Medicine, USA). The search was limited to articles in English and on humans aged >18 years. The keywords included in supplementary tables S1–S4 were used as literature search terms and limited to original studies.

## Manuscript preparation

Task force members were divided into five groups (LP and AA for CXR; DC and GSP for PET; LH, MS, MZ and KM for CT; GP and BB for LU; PS for EIT). Each group focused on a single technique and its use in a disease entity selected *a priori* by the Task Force Chairs (pneumonia, chronic obstructive

---

**Affiliations:** <sup>1</sup>SC Anestesia e Rianimazione, Ospedale San Paolo – Polo Universitario, ASST Santi Paolo e Carlo, Milan, Italy. <sup>2</sup>Dipartimento di Scienze della Salute, Centro Ricerca Coordinata di Insufficienza Respiratoria, Università degli Studi di Milano, Milan, Italy. <sup>3</sup>Casa di Cura del Policlinico, Dipartimento di Scienze Neuroriabilitative, Milan, Italy. <sup>4</sup>Corporacion Sanitaria, Universitaria Parc Tauli, CIBER de Enfermedades Respiratorias Autonomous University of Barcelona, Sabadell, Spain. <sup>5</sup>Intensive Care Dept, University Hospitals Sagrado Corazon – General de Catalunya, Quiron Salud, Barcelona-Sant Cugat del Valles, Spain. <sup>6</sup>Service d'Anesthésie – Réanimation, Université Bourgogne – Franche Comté, Incumr 866L, Dijon, France. <sup>7</sup>Dept of Nuclear Medicine, Saarland University Medical Center, Homburg, Germany. <sup>8</sup>Dept of Intensive Care Medicine, Amsterdam UMC, Vrije Universiteit Amsterdam, Amsterdam, The Netherlands. <sup>9</sup>Dept of Anesthesia, General Intensive Care Medicine and Pain Therapy, Medical University of Vienna, Vienna, Austria. <sup>10</sup>Respiratory and Critical Care Unit, Alma Mater Studiorum, University of Bologna, Sant'Orsola Malpighi Hospital, Bologna, Italy. <sup>11</sup>Cochrane Iberoamerica, Barcelona, Spain. <sup>12</sup>Mahidol–Oxford Tropical Medicine Research Unit, Mahidol University, Bangkok, Thailand. <sup>13</sup>Clinical Epidemiology and Medical Statistics Unit, Dept of Clinical and Experimental Medicine, University of Sassari, Sassari, Italy. <sup>14</sup>Dept of Anesthesiology and Critical Care Medicine, University Hospital Carl Gustav Carus, Technische Universität Dresden, Dresden, Germany. <sup>15</sup>Center for Clinical Research and Management Education, Division of Health Care Sciences, Dresden International University, Dresden, Germany. <sup>16</sup>Multimedica IRCCS, S. Giuseppe Hospital, Milan, Italy. <sup>17</sup>Anaesthesia and Intensive Care, Department of Medical and Surgical Sciences, University of Magna Graecia, Catanzaro, Italy.

**Correspondence:** Davide Chiumello, SC Anestesia e Rianimazione, ASST Santi Paolo e Carlo, Via Di Rudini, Milan, Italy. E-mail: [davide.chiumello@unimi.it](mailto:davide.chiumello@unimi.it)

pulmonary diseases (COPD), acute heart failure, pneumothorax, pleural effusion, acute lung injury and acute respiratory distress syndrome (ARDS)). For each technique, a narrative summary was provided for contextualisation, which summarised certainty of evidence and relevant features. Feedback was provided by electronic communication. This is a statement document, thus no formal assessment of the evidence quality was performed and it does not include recommendations for clinical practice. The final approved version was peer reviewed.

#### *Results of the literature search*

Figure 1 provides an overview of the literature search. The initial search identified 1833 papers. After manual screening of titles and abstracts 1220 papers were excluded and 613 were considered as potentially relevant. After evaluation of the full texts and discussion among the committee, 493 were excluded for the following reasons: 350 were case reports, 61 were reviews, 25 were deemed too small a series (the expert and the methodologist agreed on two cut-offs: 10 subjects for PET and EIT, and 20 for CXR, LUS and CT), 16 were considered to be inappropriate for subject characteristics (e.g. paediatric studies) and 41 references were discarded for other reasons.

An additional search of bibliographies and authors' personal files provided nine papers. Six additional papers were added after updating the search in September 2018. Thus, a total of 135 references were used to prepare the current statement.

### **Chest X-ray**

The studies on CXR used to prepare this statement are listed in table 1. Bedside CXR remains one of the most frequently prescribed imaging techniques, providing helpful information for the monitoring of critically ill patients. Although lots of effort has been made to improve technical aspects, numerous limitations of bedside CXR persist, including bedside attenuation factor, X-ray intensity and distance to the thorax, and synchronisation to mechanical ventilation. In addition, patients are often uncooperative and difficult to position, thus increasing procedure time and cost. All these factors may hinder the correct interpretation of CXR.

### **ARDS**

ARDS is defined by the acute onset of bilateral opacities on chest radiography not fully explained by effusions, lobar/lung collapse, nodules or oedema [1].

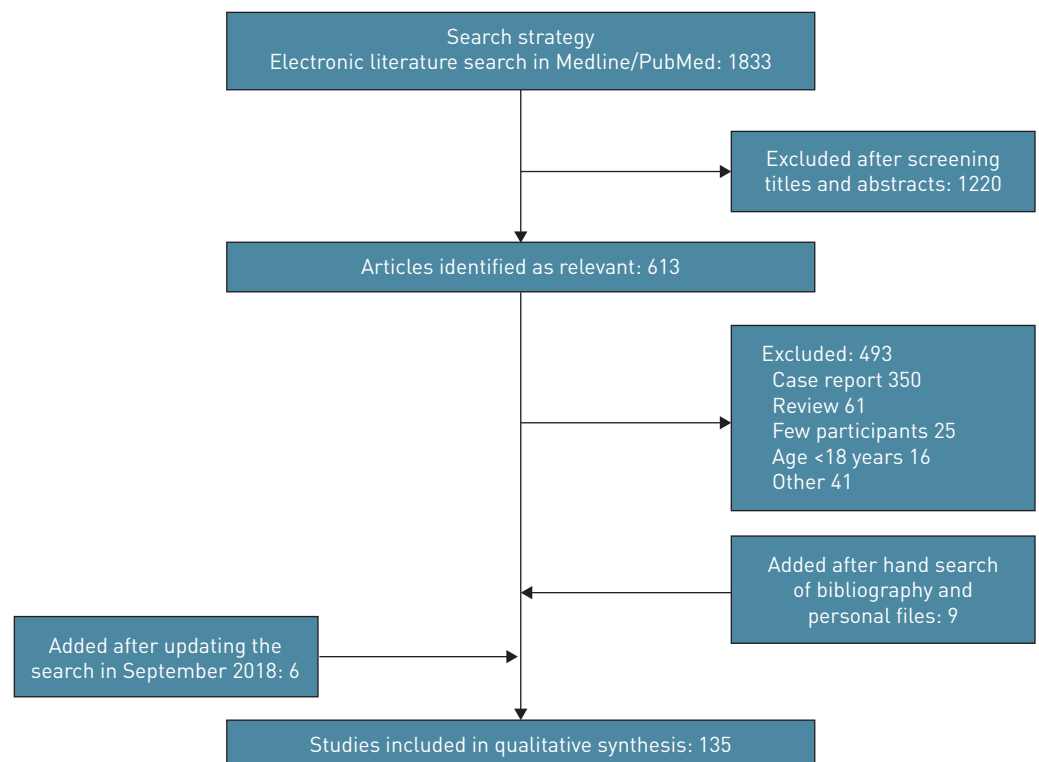


FIGURE 1 Flow chart of the study protocol process.

TABLE 1 Studies included on CXR

Disease	Reference	First author	Aim	Subjects	Study design	Main results
ARDS	[2]	Rubinfeld GD	To study the inter-observer variability in applying the American European radiographic criteria for ARDS	28	Prospective	The radiographic criteria showed high inter-observer variability
ARDS	[3]	Figueroa-Casas JB	To evaluate the diagnostic accuracy of CXRs to detect pulmonary abnormalities in ARDS	90	Retrospective	Accuracy of CXRs to detect pulmonary abnormalities was limited
ARDS	[4]	Frolich S	To evaluate accuracy of clinical diagnoses of ARDS	51	Retrospective	Only one-third of ARDS was recognised on clinical records
ARDS	[5]	Peng J-M	To examine the effect of training material on the accuracy of CXR interpretations for ARDS diagnosis	286 intensivists	Prospective	The radiographic diagnostic accuracy and inter-rater agreement were poor and not improved by training
ARDS	[6]	Goddard SL	To test an educational intervention to improve the radiographic identification of ARDS	464 intensivists	Prospective	Recognition of radiographic criteria for ARDS was low, with poor agreement
AHF	[7]	Halperin BD	To identify presence of excess lung water	12	Prospective	CXRs were not accurate in monitoring modest changes in lung water in critically ill patients
AHF	[8]	Martin GS	To identify temporal changes in fluid balance	37	Prospective	Objective radiographic measures of intravascular volume were more accurate than subjective measures
AHF	[9]	Thomason JW	To identify hydrostatic and permeability pulmonary oedema	33	Prospective	Objective measurements of CT ratio and VPW correlated with pulmonary artery occlusion pressure
AHF	[10]	Farshidpanah S	To identify hydrostatic and permeability pulmonary oedema	80	Retrospective	Objective measurements of CT ratio and VPW correlated with cardiogenic pulmonary oedema
Pneumonia	[11]	Lefcoe MS	To examine diagnostic accuracy of CXRs for pneumonia	62	Prospective	CXRs were not accurate in predicting the presence of pneumonia
Pneumonia	[12]	Butler KL	To examine diagnostic accuracy of CXRs for pneumonia	20	Prospective	CXRs did not improve the clinician's ability to diagnose pneumonia
Pneumonia	[13]	Moine P	To describe radiological features of severe community-acquired pneumococcal pneumonia	132	Prospective	CXRs were not accurate in detecting pneumonia aetiology
Pneumothorax	[14]	Schulman CI	To determine optimal time for CXRs after chest tube positioning	75	Prospective	Early CXRs excluded the development of a clinically significant pneumothorax
Pneumothorax	[15]	Pizano LR	To determine optimal time for CXRs after chest tube removal	75	Prospective	After 1 h from tube removal the CXRs identified all the pneumothoraces
Pleural effusion	[16]	Emamian SA	To determine the diagnostic accuracy of pleural effusion by CXR	24 measures	Prospective	Diagnostic accuracy of pleural effusion on supine CXRs was acceptable
Pleural effusion	[17]	Brixey AG	To determine the diagnostic accuracy of pleural effusion by CXR	61	Retrospective	Diagnostic accuracy of pleural effusion was the same between lateral and anterior-posterior CXRs

ARDS: acute respiratory distress syndrome; CXR: chest X-ray; AHF: acute heart failure; CT: chest computed tomography; VPW: vascular pedicle width.

Although the radiographic criterion of “bilateral pulmonary infiltrates or opacities” on CXR is essential for the diagnosis of ARDS, significant inter-observer variability is reported [2]. Compared to chest CT, the accuracy of CXR in identifying pulmonary abnormalities in patients meeting criteria for ARDS is limited and unrelated to disease severity, as defined by the extent of oxygenation derangement [3]. A retrospective single-centre study showed that only 31% of patients with ARDS according to the current definition presented with histopathological signs of diffuse alveolar damage (a finding pathognomonic for ARDS) [4]. A recent study evaluated whether diagnostic accuracy could be improved by an educational intervention based on a set of chest radiographs. Though some improvement in diagnostic accuracy after the educational intervention was observed, the overall accuracy remained poor [5]. A multicentre randomised trial using an online educational module of the Berlin definition on ARDS failed to demonstrate any improvement in the accuracy or in the identification of ARDS patients among critical care clinicians and research staff [6].

#### **Acute heart failure**

CXRs performed at the bedside with portable equipment are often used to identify and quantify the presence of pulmonary oedema in the intensive care unit (ICU). However, a supine position and the potential presence of other multiple radiographic abnormalities often hinder CXR interpretation. In addition, the distinction between hydrostatic and permeability pulmonary oedema, as well as quantitating the amount of lung water, is extremely problematic [7]. Although a relationship has been found between a score based on CXR findings and the amount of extravascular lung water, the evolution of extravascular lung water was not associated with score changes [7]. To improve diagnostic accuracy in patients with acute heart failure, some radiological signs, such as the cardiothoracic ratio, vascular pedicle width and dimensions of the mediastinal silhouette of the great vessels, have been proposed [8, 9]. A vascular pedicle width exceeding 70 mm has acceptable sensitivity and specificity in discriminating cardiogenic from non-cardiogenic pulmonary oedema [10].

#### **COPD**

Although CXR is usually performed in patients with COPD exacerbation, it has low sensitivity for the detection of airflow obstruction. During acute exacerbation the predominant pathological changes are found within the airways, with abnormal images only in very few cases. In this setting, CXR is useful to rule out pneumonia or to exclude alternative diagnoses and complications such as decompensated heart failure, massive pleural effusion, atelectasis or pneumothorax.

#### **Pneumonia**

Conventional CXR is the preferred imaging modality in critical care settings for both the detection of new infiltrates and for monitoring response to therapy, with the possibility of detecting early complications including cavitations, abscesses, pneumothoraces and pleural effusions. However, owing to the well-known difficulties involved in radiographic interpretation of portable CXR in critical care, a diagnosis of pneumonia may be difficult. Using protected brush catheter specimens as the gold standard for the diagnosis of nosocomial pneumonia, LEFCOE *et al.* [11] demonstrated a CXR sensitivity in detecting pneumonia associated with positive cultures of 0.60 and 0.64, as interpreted by two radiologists, with low reproducibility between the two examiners. In a small group of patients with clinical suspicion of ventilator-associated pneumonia, the sensitivity of CXR in determining the presence of ventilator-associated pneumonia was 25%, with a specificity of 75% and an accuracy of 0.45 using protected brush catheter and microbiology as reference [12]. A multicentre French study found that the occurrence of alveolar consolidations with lobar distribution was more frequently associated with severe pneumococcal pneumonia, although the value of this prediction was rather limited [13].

#### **Pneumothorax**

Controversy exists regarding the optimal time interval to identify a pneumothorax on CXR after both chest tube positioning and removal. SCHULMAN *et al.* [14] evaluated both an immediate and a delayed approach (following morning) with CXR after chest tube positioning. Of the 31 patients with a pneumothorax on follow-up, 22 were “early” and nine “late”, but none of the patients in the late group presented with a clinically significant pneumothorax. Concerning the timing of CXRs after tube removal, PIZANO *et al.* [15] found that serial CXRs performed at approximately 1, 10 and 36 h did not identify different rates of pneumothoraces in mechanically ventilated patients.

#### **Pleural effusion**

Owing to technical limitations, pleural effusions, particularly when small, can be difficult to diagnose on CXR performed in a supine position. A previous report on the detection of pleural effusions on supine

CXR showed an overall accuracy of 82%, with better results for larger pleural effusions (>300 mL) [16]. The accuracy for parapneumonic effusions is similar for anteroposterior and lateral CXR [17].

### Ultrasound

The studies on LU used to prepare this statement are listed in table 2. Because the ultrasound beam does not penetrate the lung, LU is able to explore only the pleural line and the related artefacts that are generated at the pleural line. The pleural line appears as a hyperechoic sliding line, moving forwards and backwards in the course of inspiration and expiration. The key artefacts are A- and B-lines. B-lines correspond to various degrees of lung aeration and the quantity is related to the amount of extravascular lung water. Multiple and well-separated vertical B-lines correspond to a moderate decrease in lung aeration resulting from interstitial syndrome. Coalescent B-lines correspond to a more severe decrease in lung aeration resulting from partial filling of alveolar spaces by pulmonary oedema or confluent bronchopneumonia. Lung consolidation is a tissue-like echotexture pattern due to a loss of aeration of lung parenchyma [18].

### ARDS

Lung infiltrates of the pulmonary alveolar interstitial space caused by ARDS may show consolidations and B-line patterns. However, these findings are nonspecific of ARDS because the syndrome encompasses consolidated regions, ground glass areas and normally aerated regions. As a consequence, LU patterns of ARDS may encompass B-lines, pleural line abnormalities (absent or reduced lung sliding, thickening or irregularities), consolidations and spared areas [19, 20]. These LU findings, together with impaired oxygenation, are simple tools to diagnose ARDS [21, 21], especially when combined with echocardiography [22]. LU has helped assess the incidence and outcomes of patients with ARDS in settings with limited resources [23].

The increase of lung water in ARDS can be detected by LU, and the LU score of B-lines is closely related to several prognostic indices [24].

Given that LU patterns are determined by the level of aeration, lung re-aeration can be assessed by tracking LU changes. This was first demonstrated by trans-oesophageal echography [25–27]. It has been proven that during positive end-expiratory pressure (PEEP) recruitment manoeuvres, the gas increase can be monitored by measuring the area of consolidated, dependent right lower lobes [28]. However, it may be more accurate to use scores based on a whole lung examination protocol [29]. Despite the fact that LU scores have proven to be a valid tool for assessing regional and global lung aeration, global LU score variations should not be used for bedside assessment of PEEP-induced recruitment. In addition, LU cannot be used to estimate lung hyperinflation [30].

### Acute heart failure

Although nonspecific, B-lines can detect extravascular lung water. Simple scores based on numbers of B-lines correlate with surrogate markers of pulmonary oedema [31–33] because B-lines decrease during haemodialysis [34, 35]. B-lines could also be correlated with pulmonary wedge pressure [24, 36].

Cardiogenic pulmonary oedema results from increased intravascular hydrostatic pressure. As a consequence, the distribution of alveolar flooding is homogeneous. The LU pattern of cardiogenic pulmonary oedema is characterised by the presence of multiple B-lines in all thoracic regions [19]. Pleural effusion, moderately or severely decreased left ventricular function, and a small inferior vena cava diameter point towards cardiogenic pulmonary oedema instead of ARDS in acutely hypoxaemic patients [20]. LU has been used in the pre-hospital setting [37] and in the emergency department to manage patients with cardiogenic pulmonary oedema, thus proving to be a reliable bedside tool to guide therapy [38, 39].

### COPD

In COPD patients, acute exacerbation usually shows a normal LU pattern despite the presence of acute respiratory failure. On the contrary, the presence of B-lines suggests the presence of an associated alveolar interstitial syndrome with an acceptable accuracy [40]. Chest ultrasonography (heart and lung) in patients admitted with acute respiratory failure allows a more accurate diagnosis of decompensated COPD compared to a standard diagnostic approach, based on physical examination, CXR and biological data [41].

### Pneumonia

LU is a valid alternative for bedside diagnosis of lung consolidations in community-acquired pneumonia in adults [42], and can provide early detection of interstitial lung involvement in viral pneumonia [43]. In addition, LU can also provide guidance for transthoracic needle aspiration for aetiological diagnosis of patients with complicated pneumonia. This has been confirmed in the ICU and the emergency department [44–52].

TABLE 2 Studies included on LU

Disease	Reference	First author	Aim	Subjects	Study design	Main results
ARDS	[19]	Copetti R	To assess the ability of LU to identify ARDS compared to cardiogenic pulmonary oedema	58	Prospective	LU was able to discriminate between ARDS and cardiogenic pulmonary oedema
ARDS	[20]	Sekiguchi H	To assess the ability of LU to identify ARDS compared to cardiogenic pulmonary oedema	134	Prospective	LU was able to discriminate between ARDS and cardiogenic pulmonary oedema
ARDS	[21]	Bass CM	To assess the ability of LU and arterial saturation to identify ARDS	123	Prospective	LU was a useful tool to screen oxygenation impairment consistent with ARDS
ARDS	[22]	Huang D	To assess the ability of LU to identify ARDS in elderly patients	51	Prospective	LU presented similar accuracy compared to chest CT
ARDS	[23]	Riviello ED	To estimate incidence of ARDS according to the Berlin definition and LU	42	Prospective	Using these criteria the incidence of ARDS was significantly improved
ARDS	[24]	Zhao Z	To assess prognostic values of LU in ARDS	21	Prospective	Early use of LU was a useful prognostic indicator in ARDS patients
ARDS	[25]	Tsubo T	To evaluate daily lung density changes in ARDS	15	Prospective	LU was able to detect density changes in independent lung regions in ARDS
ARDS	[26]	Tsubo T	To evaluate lung density in ARDS	40	Prospective	LU was able to detect density changes in independent lung regions in ARDS
ARDS	[27]	Tsubo T	To evaluate lung density in ARDS during prone positioning	10	Prospective	LU was able to detect changes in density during prone positioning
ARDS	[28]	Stefanidis K	To evaluate LU in the measurement of pulmonary recruitment	10	Prospective	LU could detect non-aerated lung areas during PEEP trials
ARDS	[29]	Bouhemad B	To evaluate LU in the measurement of pulmonary recruitment	30	Prospective	LU could detect lung recruitment during PEEP changes
ARDS	[30]	Chiumello D	To assess LU score in the measurement of pulmonary recruitment	20	Prospective	LU score should not be used to assess pulmonary recruitment
AHF	[31]	Enghard P	To evaluate LU in predicting extravascular lung water	50	Prospective	LU correlated with extravascular lung water
AHF	[32]	Jambrick Z	To evaluate LU in predicting extravascular lung water	121	Prospective	LU correlated with extravascular lung water
AHF	[33]	Volpicelli G	To evaluate LU in predicting extravascular lung water	73	Prospective	LU correlated with extravascular lung water
AHF	[34]	Mallamaci F	To evaluate LU in predicting extravascular lung water	47	Prospective	LU correlated with extravascular lung water in haemodialysis patients
AHF	[35]	Noble VE	To evaluate LU in predicting extravascular lung water	45	Prospective	LU score changes correlated with real time extravascular lung water changes during haemodialysis
AHF	[36]	Lichtenstein DA	To evaluate LU in predicting pulmonary arterial occlusion pressure	102	Prospective	LU score could predict a low pulmonary arterial occlusion pressure
AHF	[37]	Laursen CB	To evaluate LU in predicting the diagnosis of cardiogenic pulmonary oedema	40	Prospective	LU was able to rule out cardiogenic pulmonary oedema
AHF	[38]	Cortellaro F	To evaluate LU in monitoring the response to therapy in cardiogenic pulmonary oedema	41	Prospective	LU allowed to guide therapy titration in cardiogenic pulmonary oedema
AHF	[39]	Martindale JL	To evaluate LU in monitoring changes in pulmonary oedema	20	Prospective	LU improved the clinical management
COPD	[40]	Lichtenstein DA	To assess the relationship between comet tail artefacts and alveolar interstitial syndrome	121	Prospective	Good correlation between the ground glass and comet tail artefacts
COPD	[41]	Silva S	To compare LU with clinical, radiological and biological data	78	Prospective	Cardiothoracic ultrasound was a useful diagnostic approach
Pneumonia	[42]	Yang PC	To identify LU features associated with pneumonia	161	Prospective	LU was a useful tool in the evaluation of pulmonary consolidation

Continued

TABLE 2 Continued

Disease	Reference	First author	Aim	Subjects	Study design	Main results
Pneumonia	[43]	Testa A	To evaluate LU features in interstitial pneumonia	98	Prospective	LU could provide early detection of interstitial pneumonia
Pneumonia	[44]	Reissig A	To identify LU features associated with pneumonia	30	Prospective	LU was a useful tool in the evaluation and follow-up of patients with pneumonia
Pneumonia	[45]	Parlamento S	To evaluate LU in confirming the clinical suspicion of pneumonia	49	Prospective	LU should be considered in the diagnostic workup of pneumonia
Pneumonia	[46]	Sperandeo M	To evaluate LU in confirming the clinical suspicion of pneumonia	15	Prospective	LU was a useful tool in the evaluation and follow-up of patients with pneumonia
Pneumonia	[47]	Cortellaro F	To evaluate LU to confirm the clinical suspicion of pneumonia	120	Prospective	LU should be considered in the diagnostic workup of pneumonia
Pneumonia	[48]	Reissig A	To evaluate LU in the diagnosis of community-acquired pneumonia	30	Prospective	LU had a high accuracy in diagnosing community-acquired pneumonia
Pneumonia	[49]	Bourcier J-E	To evaluate LU in confirming the clinical suspicion of pneumonia	144	Prospective	LU should be considered as a first-line diagnostic tool for pneumonia
Pneumonia	[50]	Corradi F	To compare LU with CXR in suspected community-acquired pneumonia	32	Prospective	LU should be considered in the first-line diagnosis of pneumonia
Pneumonia	[51]	Liu X	To compare LU with CXR in suspected community-acquired pneumonia	179	Prospective	LU had better diagnostic sensitivity and accuracy for diagnosing community-acquired pneumonia
Pneumonia	[52]	Pagano A	To compare LU with CXR in suspected community-acquired pneumonia	107	Prospective	LU should be considered in the first-line diagnosis of pneumonia
Pneumonia	[53]	Lichtenstein DA	To evaluate LU features and diagnosis of pneumonia	66	Prospective	LU could distinguish pneumonia from reabsorption atelectasis
Pneumonia	[54]	Bouhemad B	To evaluate LU for lung re-aeration in ventilator-associated pneumonia	30	Prospective	LU accurately estimated lung re-aeration
Pneumonia	[55]	Mongodi S	To evaluate LU for early diagnosis of ventilator-associated pneumonia	99	Prospective	LU was a reliable tool for early ventilator-associated pneumonia diagnosis
Pneumothorax	[56]	Lichtenstein DA	To evaluate the presence of lung point as specific sign of pneumothorax	66	Prospective	The lung point allowed the diagnosis of pneumothorax
Pneumothorax	[57]	Volpicelli G	To compare the pneumothorax volume between LU and chest CT	124	Prospective	Good correlation between LU and chest CT
Pneumothorax	[58]	Dulchavsky SA	To evaluate LU for diagnosis of pneumothorax	382	Prospective	LU was a reliable tool for diagnosis of pneumothorax
Pneumothorax	[59]	Kirkpatrick AW	To evaluate LU for diagnosis of pneumothorax	225	Prospective	LU was a reliable tool for diagnosis of pneumothorax
Pneumothorax	[60]	Weekes AJ	To compare LU with CXR for confirmation of central venous catheter placement	151	Prospective	No difference between LU and CXR
Pneumothorax	[61]	Vezzani A	To compare LU with CXR for confirmation of central venous catheter placement	111	Prospective	No difference between LU and CXR
Pneumothorax	[62]	Maury E	To compare LU with CXR for confirmation of central venous catheter placement	58	Prospective	LU was a more rapid method compared to CXR
Pneumothorax	[63]	Saucier S	To evaluate LU for the detection of pneumothorax after chest tube removal	50	Prospective	LU was accurate to detect pneumothorax
Pleural effusion	[64]	Lichtenstein DA	To evaluate the safety of thoracentesis guided by LU	40	Prospective	LU guaranteed safety during thoracentesis
Pleural effusion	[65]	Vignon P	To assess the ability of LU to predict the amount of pleural effusion	97	Prospective	Expiratory interpleural distance was related to the amount of pleural effusion
Pleural effusion	[66]	Rozycki GS	To evaluate LU for diagnosis of pleural effusion	47	Prospective	LU was a reliable tool for the diagnosis of pleural effusion in surgically ill patients

Continued



TABLE 2 Continued

Disease	Reference	First author	Aim	Subjects	Study design	Main results
Pleural effusion	[67]	Rocco M	To compare LU with CXR in trauma patients	15	Prospective	LU was a reliable tool for diagnosis of pleural effusion in trauma patients
Pleural effusion	[68]	Gallard E	To evaluate LU in patients with acute dyspnoea in the emergency department	130	Prospective	LU permitted rapid detection of pleural effusion in presence of acute dyspnoea
Pleural effusion	[69]	Yu CJ	To assess the ability of LU to predict the amount of pleural effusion	320	Prospective	LU accurately detected pleural effusion in critically ill patients
Pleural effusion	[70]	Mayo PM	To assess the safety of ultrasound-guided thoracentesis	211	Prospective	Ultrasound thoracentesis in mechanical ventilation was a well-tolerated procedure
Pleural effusion	[71]	Schleder S	To evaluate hand-carried LU for the diagnosis of pleural effusion	24	Prospective	Hand-carried LU had high diagnostic accuracy

LU: lung ultrasound; ARDS: acute respiratory distress syndrome; CT: computed tomography; PEEP: positive end-expiratory pressure; AHF: acute heart failure; COPD: chronic obstructive pulmonary disease; CXR: chest X-ray.

Performing an accurate diagnosis of ventilator-associated pneumonia in mechanically ventilated patients frequently represents a challenge. By identifying ventilator-associated pneumonia-specific signs (focal areas of interstitial syndrome, small subpleural consolidations, large consolidations and fluid bronchogram), LU can discriminate pneumonia from resorptive atelectasis [53]. Furthermore, LU can accurately estimate the changes in lung aeration in patients with ventilator-associated pneumonia treated with antibiotics [54].

In a multicentre study, the diagnostic performance of a score based on the presence of subpleural consolidations, lobar consolidations and dynamic arborescent/linear air bronchograms was investigated in patients with suspected ventilator-associated pneumonia [55]. The LU-based score had a higher sensitivity and specificity in predicting ventilator-associated pneumonia than the clinical-based score (*i.e.* the Clinical Pulmonary Infection Score) [55].

### ***Pneumothorax***

Pneumothorax is the interposition of gas between visceral and parietal pleura. LU findings in pneumothorax are A-lines and the absence of lung sliding, B-lines and visualisation of a lung point [56]. The lung point corresponds to the area on the chest wall adjacent to the pneumothorax where the respiratory movement of the lung reappears. This transition between sliding and non-sliding pattern represents the limit of the pneumothorax and is a measure of its extension and volume [57].

In trauma patients in the emergency department, LU performs better than CXR in diagnosing pneumothoraces and can also detect the presence of occult pneumothoraces [58, 59]. A CXR is routinely requested after central venous catheter placement to exclude the presence of an iatrogenic pneumothorax. LU combined with contrast-enhanced ultrasonography has high accuracy in excluding both a pneumothorax and catheter malposition [60, 61], with a significant reduction in the mean time required for the examination [62]. In addition, LU can be used to exclude a pneumothorax, as an alternative to CXR, after chest tube removal [63].

### ***Pleural effusion***

LU can reliably identify free pleural effusion that appears as a dependent echo-free space between the parietal and visceral pleura [64]. LU may also allow semi-quantitative, clinically useful estimations of effusion volume. The expiratory interpleural distance measured at the thoracic base with ultrasonography has been proven to correlate with the fluid volume [65]; LU is able to detect pleural effusion in different clinical conditions, irrespective of the underlying disorder [66–69].

Ultrasound-guided thoracentesis in patients receiving mechanical ventilation reduces the risk of pneumothorax to <1% [70].

Miniaturised ultrasound systems such as hand-carried ultrasound imagers are now available. These systems allow a more prompt bedside diagnosis and immediate therapeutic measures, and could provide a helpful technique for the primary assessment of pleural effusions [71].

## **Computed tomography**

The studies on CT used to prepare this statement are listed in table 3. CT scanning is frequently performed in critically ill patients, either at admission or later in cases of worsening respiratory failure. A retrospective analysis conducted in medical critically ill patients reported that a CT scan was performed in 11.5% of all patients admitted to the ICU [72]. Consolidations, pleural effusions and parenchymal abnormalities were each present in more than one-fifth of the patients. The most common CT findings included consolidations (46%), other parenchymal abnormalities (29%) and pleural effusions (35%). Clinical changes clearly linked to chest CT were observed in 24% of the patients [72].

## **ARDS**

### ***Description of the findings***

Since the first description of chest CT in ARDS, the described disease patterns have included ground glass opacifications, parenchymal distortion, areas of consolidation, and reticular and linear opacities [73]. These alterations detected by CT scan are significantly related to the impairment of gas exchange and to the lung injury score [74]. ARDS patients are characterised by a lower end-expiratory lung gas volume and an increase in lung oedema with a typical diffuse or patchy distribution of attenuation in the lung [75–77]. However, owing to the inhomogeneous distribution of the disease, a single-slice CT, compared to an overall lung study, cannot accurately describe the amount of reopening of collapsed lung regions due to PEEP changes [78]. An important technical issue with CT is the spatial resolution. VIEIRA *et al.* [79] demonstrated that low spatial resolution CT can underestimate the degree of hyperinflation due to PEEP compared to high spatial resolution CT, particularly when the lung morphology has a focal loss of aeration.

TABLE 3 Studies included on CT

Disease	Reference	First author	Aim	Subjects	Study design	Main results
ARDS	[72]	Awerbuch E	To evaluate the diagnostic and clinical impact of CT	134	Retrospective	Up to one-quarter of patients had clinical changes
ARDS	[73]	Owens CM	To compare morphological CT abnormalities with severity of lung injury score	8	Prospective	Extent of CT abnormalities correlated with lung injury score
ARDS	[74]	Bombino M	To compare CT and CXR with clinical data	17	Prospective	CT and CXR scores were related to the degree of gas exchange impairment
ARDS	[75]	Puybasset L	To compare CT distribution of gas and tissue analysis in ARDS and healthy subjects	82	Prospective	Different lung morphologies corresponded to different distributions of gas within the lung
ARDS	[76]	Patroniti N	To compare helium dilution technique with CT to assess lung gas volume in patients with ARDS	21	Prospective	Helium dilution technique showed good agreement with CT
ARDS	[77]	Patroniti N	To compare CT and indocyanine green dye double dilution technique for measurement of pulmonary oedema in ARDS	14	Prospective	Estimation of oedema with indocyanine green showed good correlation and reproducibility with CT
ARDS	[78]	Lu Q	To assess PEEP changes in single- or three-section, or whole lung CT	39	Retrospective	Single- and three-section differed from whole lung CT
ARDS	[79]	Vieira SRR	To compare pulmonary hyperinflation measured by low and high spatial resolution CT	30	Prospective	In ARDS accurate estimation of lung hyperinflation on CT required high spatial resolution
ARDS	[80]	Reske AW	To evaluate the ratio between $P_{aO_2}/F_{iO_2}$ and shunt	71	Prospective	Logarithmic $P_{aO_2}/F_{iO_2}$ allowed estimation of CT shunt and its changes
ARDS	[81]	Caironi P	To assess a standardised low PEEP strategy	148	Retrospective	The $P_{aO_2}/F_{iO_2}$ computed at 5 cmH <sub>2</sub> O of PEEP accurately reflected the lung injury severity and recruitability
ARDS	[82]	Rouby JJ	To assess differences in lung morphology with different lung mechanics and outcome	71	Prospective	A severity score based on CT lung morphology accurately identified patients with the most severe forms of ARDS
ARDS	[83]	Stelter L	To evaluate CT findings in patients with sepsis and ARDS	36	Prospective	A CT scoring system based on pulmonary findings was related to the outcome
ARDS	[84]	Lazoura O	To correlate CT morphology with clinical severity and outcome	33	Retrospective	A greater extent of airspace disease was associated with higher clinical severity
ARDS	[85]	Simon M	To assess clinical utility of CT	204	Retrospective	CT yielded useful information for diagnosis, prognosis and alternative diagnosis in ARDS patients
ARDS	[86]	Chiumello D	To investigate if low-dose CT can provide accurate quantitative and visual anatomical results	45	Prospective	Low-dose CT showed good agreement with conventional CT both for quantitative and visual anatomical results
ARDS	[87]	Klapsing P	To investigate an automatic software programme for quantitative lung analysis	10	Prospective	Automatic software computation allowed accurate computation
ARDS	[88]	Miller PR	To identify high-risk patients according to pulmonary contusion volume	49	Prospective	Contusion volume on chest CT was predictive for ARDS development
ARDS	[89]	Reske AW	To evaluate quantitative CT in post-traumatic lung dysfunction	78	Prospective	Quantitative CT might help to discriminate atelectasis from consolidation
ARDS	[90]	Chiumello D	To assess the effect of pleural effusion on respiratory mechanics, gas exchange and lung recruitability	179	Prospective	Pleural effusion was of modest entity and did not affect respiratory system elastance
ARDS	[91]	Gattinoni L	To assess CT changes in early and late ARDS	81	Prospective	Lung structure markedly changed with ARDS duration
ARDS	[92]	Treggiari MM	To investigate prevalence/distribution of air cysts and bronchiectasis	21	Retrospective	A predominant localisation of lesions in better ventilated areas (non-dependent)
ARDS	[93]	Burnham EL	To determine the relationship between pulmonary dysfunction and high-resolution CT	89	Prospective	Among survivors, high-resolution CT findings correlated with quality of life

Continued

TABLE 3 Continued

Disease	Reference	First author	Aim	Subjects	Study design	Main results
ARDS	[94]	Nobauer IM	To evaluate changes in high-resolution CT 6–10 months after ARDS	15	Prospective	ARDS frequently resulted in fibrotic changes in the lung, particularly in the ventral regions
ARDS	[95]	Masclans JR	To evaluate the quality of life in survivors of ARDS and related CT changes	38	Prospective	6 months after ARDS, there were mild radiological abnormalities in 76% of patients
ARDS	[96]	Kim SJ	To determine if outcome differs between pulmonary and extrapulmonary ARDS	29	Retrospective	Pulmonary lesions were more extensive in pulmonary compared to non-pulmonary ARDS
ARDS	[97]	Cressoni M	To assess the relationship between lung recruitability and pressure to overcome the compression forces	51	Prospective	Lung recruitability was not related to the pressure to overcome compression forces
ARDS	[98]	Puybasset L	To evaluate PEEP changes and lung morphology	71	Retrospective	PEEP effects were more related to lung morphology than the cause of lung injury
ARDS	[99]	Constantin J-M	To determine if differences in lung morphology predict the response to recruitment manoeuvres	19	Prospective	Lung morphology predicted response to recruitment; focal lung morphology was at high risk for hyperinflation with recruitment manoeuvre
ARDS	[100]	Chiumello D	To evaluate the effects of body mass index in ARDS	101	Retrospective	Obese patients with ARDS had similar chest wall elastance and lung recruitability compared to non-obese ARDS patients
ARDS	[101]	Cressoni M	To assess the amount of lung recruitability and opening and closing	33	Prospective	PEEP up to 25 cmH <sub>2</sub> O and plateau pressure up to 30 cmH <sub>2</sub> O were not adequate to keep the lung open
ARDS	[102]	Cressoni M	To quantify lung inhomogeneity	148	Retrospective	Lung inhomogeneity was related to disease severity and mortality
ARDS	[103]	Chiumello D	To determine if bedside PEEP selection is related to lung recruitability	51	Prospective	Oxygenation based method provided PEEP related to lung recruitability
ARDS	[104]	Constantin J-M	To compare two recruitment manoeuvres in ARDS	19	Prospective	Extended sigh promoted higher alveolar recruitment and oxygenation compared to CPAP RM
ARDS	[105]	Galiatsou	To quantify lung volume changes during prone position	21	Prospective	Prone position recruited significantly more lung compared to recruitment manoeuvre
ARDS	[106]	Lu Q	To evaluate the effects of exogenous surfactant on pulmonary aeration in patients with ARDS	20	Prospective	Surfactant administration induced an improvement in lung aeration of poorly and non-aerated lung regions
ARDS	[107]	Lu Q	To compare PV curves and CT during PEEP-induced lung recruitment	19	Prospective	Alveolar recruitment assessed by CT and PV curve were strongly correlated but with very high limits of agreements
ARDS	[108]	Yoshida T	To compare airway pressure release ventilation compared to PSV on lung atelectasis	18	Retrospective	Airway pressure released ventilation resulted in better lung aeration compared to PSV
ARDS	[109]	Varpula T	To compare airway pressure release ventilation compared to PSV on lung atelectasis and gas distribution	23	Retrospective	No differences in airway pressure release ventilation or PSV on CT characteristics
AHF	[110]	Saguel B	To compare CT estimation of cardiac preload and pulmonary hydration in predicting volume status	30	Prospective	CT estimation of end diastolic volume index and extravascular lung water were not accurate in predicting volume status
AHF	[111]	Zhang F	To evaluate quantitative CT analysis to measure pulmonary oedema	10	Prospective	Acceptable agreement between CT analysis and thermodilution
AHF	[112]	Vergani G	To compare quantitative CT analysis in cardiogenic pulmonary oedema and ARDS	80	Prospective	Similar presence of ground glass and different airspace consolidation regions
Pneumonia	[113]	Syrialia H		47	Prospective	CT was more sensitive than CXR

Continued

TABLE 3 Continued

Disease	Reference	First author	Aim	Subjects	Study design	Main results
Pneumonia	[114]	Gruden JF	To compare CT with CXR in the diagnosis of pneumonia	33	Prospective	CT was more sensitive than CXR
Pneumonia	[115]	Claessens Y-E	To compare CT with CXR in AIDS patients	319	Prospective	CT was more sensitive than CXR
Pneumonia	[116]	Hockstein NG	To compare CT with CXR in the diagnosis of community-acquired pneumonia			
			To compare CT with electronic nose sensor	33	Prospective	Acceptable agreement between CT and nose sensor for pneumonia
COPD	[117]	Nieskowska A	To assess the regional distribution of inflation in COPD	32	Prospective	PEEP significantly increased lung overinflation
COPD	[118]	Bahloul M	To assess the incidence and outcome of pulmonary embolism in COPD	131	Retrospective	Higher mortality and length of stay in COPD patients with an acute exacerbation and pulmonary embolism
Pneumothorax	[119]	Lichtenstein DA	To compare CT with LU in the diagnosis of occult pneumothorax	200	Retrospective	LU might decrease the need for CT
Pneumothorax	[120]	Soldati G	To compare CT with LU in the diagnosis of occult pneumothorax	109	Prospective	LU might decrease the need for CT
Pneumothorax	[121]	Xirouchaki N	To compare CT with LU and CXR	42	Prospective	LU could be an alternative to CT
Pleural effusion	[122]	Remerand F	To assess the accuracy of LU to measure pleural effusion	58	Prospective	The multiplane LU approach estimated pleural effusion volume better than the conventional technique

CT: computed tomography; ARDS: acute respiratory distress syndrome; CXR: chest X-ray; PEEP: positive end-expiratory pressure;  $P_{aO_2}$ : arterial oxygen tension;  $F_{iO_2}$ : fraction of inspired oxygen; CPAP: continuous positive airway pressure; RM: remote monitoring; PSV: pressure support ventilation; AHF: acute heart failure; COPD: chronic obstructive pulmonary disease; LU: lung ultrasound.

ARDS is characterised by different levels of hypoxaemia due to different amounts of non-aerated lung regions (*i.e.* alveolar shunt), which can be precisely quantified by CT. The logarithmically transformed arterial oxygen tension ( $P_{aO_2}$ )/inspiratory oxygen fraction ( $F_{iO_2}$ ) due to pure oxygen ventilation allows CT shunt to be estimated [80]. According to the recent Berlin definition of ARDS that proposed three exclusive categories according to the degree of hypoxaemia, a PEEP of 5 cmH<sub>2</sub>O should be applied to stratify patients at intensive care admission. This relatively low PEEP level is accurate in predicting the severity of hypoxaemia and the recruitability of the lung compared to higher PEEP levels [81]. At 5 cmH<sub>2</sub>O of PEEP the potential for lung recruitment is significantly different according to each ARDS category of the Berlin definition, being two and three times higher in patients with moderate and severe ARDS compared to mild ARDS [81], suggesting that low PEEP levels should be applied upon intensive care admission to stratify patients according to the severity of disease.

Patients with diffuse attenuations have a higher mortality rate compared to lobar attenuations [82]. In one study, up to 50% of patients with sepsis and ARDS had a CT scan score higher than that of survivors and fewer ground glass opacities [83]. Pulmonary findings on CT did not allow discrimination between a pulmonary and extrapulmonary focus of infection [83].

In a study of patients with ARDS caused by H1N1 influenza, the amounts of total lung consolidation and ground glass opacity were not different. However, the total lung consolidation significantly increased, whereas total lung ground glass opacity decreased from the anterior towards the posterior. The total lung disease was significantly higher in patients who required extracorporeal membrane oxygenation (ECMO) compared to those who did not require ECMO [84]. Chest CT has substantially changed the understanding and management of patients with ARDS. SIMON *et al.* [85] reported that chest CT affected treatment in 27% of cases, in particular resulting in alteration in antibiotic therapy (8%), drainage of pleural fluid (8%) and modification in antimycotic therapy (4%). Major disadvantages of CT are that the patient has to be transported to the radiological department and the radiation exposure. CHIUMELLO *et al.* [86] demonstrated that low-dose CT has a high agreement with conventional CT for quantitative analysis in ARDS patients. The current standard technique for quantitative CT scan analysis is based on a manual lung segmentation, which is time-consuming and depends on the skill of the operator. Klapsing *et al.* [87] reported very good precision for an automatic lung segmentation software program compared to manual segmentation. This automatic lung CT segmentation was able to reduce the processing time by >99%.

Trauma patients are at risk for developing ARDS, and CT could be used to detect possible lung and heart disease [85]. In a study of chest trauma patients with pulmonary contusion, the volume of the contusion was related to higher risk of ARDS [88]. Quantitative CT scan analysis offers the possibility of computing the total lung weight and could be used to discriminate lung atelectasis from consolidation. In a group of trauma patients with ARDS, 60% of the patients had a lung weight volume similar to that of trauma patients without ARDS, suggesting a higher amount of atelectasis compared to consolidation [89].

In the early phase of ARDS, the amount of pleural effusion is quite modest (an average of 340 mL) and does not affect the respiratory system elastance, amount of lung collapse or degree of oxygenation [90].

#### *Treatment effect*

Chest CT has been used to determine complications of mechanical ventilation or in the follow-up of ARDS patients. Late ARDS has a significantly higher incidence of pneumothoraces and number of bullae compared to early ARDS [91]. TREGGIARI *et al.* [92] performed chest CT in ARDS patients on prolonged ventilation (interval between ARDS and CT scan 22±19 days). They found that development of air cysts and bronchiectasis in ventilated patients with ARDS mainly occurred in non-dependent lung regions and severity correlated with peak pressures.

Although the mortality rate of ARDS patients has significantly decreased through the years, it still ranges between 40% and 50%, with surviving patients having a significant reduction in their quality of life. In a study of acute lung injury survivors, decrements in quality of life attributable to pulmonary dysfunction were strongly associated with higher radiological scores [93]. In a small study, 87% of patients with ARDS (13 out of 15) exhibited fibrotic changes in the lung, in particular in the ventral parts, as assessed by high-resolution CT [94]. A significant correlation was found between the severity of ARDS and the severity of CT findings. In a subsequent study [95], lung abnormalities were found on high-resolution CT in 75% of patients 6 months after recovery. A reticular pattern was the most frequent finding. A predominance for the ventral parts was noted in 37% of the patients. KIM *et al.* [96] found that patients with pulmonary ARDS had more severe lung sequelae on chest CT after 20±12 months compared to patients with extrapulmonary ARDS.

CT has previously been used to evaluate or predict the response to PEEP changes and to recruitment manoeuvres in patients with ARDS [97]. Analysing lung recruitability as the decrease in non-aerated tissue

from 5 to 45 cmH<sub>2</sub>O of PEEP, an average of 15% of the total lung tissue was found to be unrelated to the amount of compressive forces (lung oedema and characteristics of the chest wall). This suggests that the amount of PEEP required to keep the lung open is independent of the amount of tissue which should be kept open, and that factors such as the distribution of oedema within the lung being mainly intra- or extra-alveolar and the nature of the disease play an important role [97]. In patients with diffuse attenuation, PEEP induced significant alveolar recruitment without over-distension; in patients with lobar CT attenuation, PEEP induced mild alveolar recruitment with over-distension of the already inflated lung regions [98]. Patients with focal ARDS at zero end-expiratory pressure are at increased risk of hyperinflation during recruitment manoeuvres and are less likely to show recruitment compared to patients with a non-focal lung morphology [99]. The effect of body mass index in ARDS is not associated with significant differences in lung recruitability and respiratory mechanics [100]. In addition, according to protective ventilation, between 10% and 30% of the potentially recruitable lung always remains closed. Furthermore, increasing PEEP up to 15 cmH<sub>2</sub>O does not prevent the cyclic lung tissue opening and closing [101].

In an ARDS lung the distribution of the lesions (consolidations and atelectases) is inhomogeneous, promoting a regional increase in transpulmonary pressure, acting as stress raiser. Thus, a safe transpulmonary pressure could become harmful (*i.e.* reaching high levels) in the presence of stress raisers. It has been found that the extent of lung inhomogeneity increases with the severity of ARDS; increasing PEEP significantly decreases the amount of lung inhomogeneity [102].

Randomised clinical trials comparing high and low PEEP values in ARDS have not found any difference in the outcome, probably owing to several factors not being taken into account, such as the potential for lung recruitability, the amount of oedema or disease severity. When different PEEP selection methods (based on lung mechanics, oesophageal pressure and oxygenation) were compared according to lung recruitability, the oxygenation method provided higher PEEP levels (*i.e.* higher PEEP in patients with higher recruitability) [103].

CONSTANTIN *et al.* [104] compared two recruitment manoeuvres, CPAP with 40 cmH<sub>2</sub>O for 40 s versus PEEP maintained at 10 cmH<sub>2</sub>O above the lower inflection point of the pressure volume curve for 15 min. Although the increase in oxygenation was different, lung recruitment estimated by CT was significantly lower with the CPAP manoeuvre. GALIATSOU *et al.* [105] demonstrated that pronation in patients with ARDS recruited lung tissue in dependent lung areas and reversed overinflation of the ventral areas. Surfactant deficiency in ARDS also contributes to alveolar derecruitment. The administration of surfactant in mechanically ventilated patients is associated with a significant increase in the volume of gas in poorly/non-aerated lung areas and a significant increase in tissue volume in normally aerated lung areas [106]. Concerning the estimation of lung recruitment with CT or the pressure volume curve, they are well related despite having very large limits of agreement [107].

Two studies have used CT to compare different ventilator modes on lung aeration in patients with ARDS [108, 109]. The first found that airway pressure release ventilation significantly decreases the amount of atelectasis and increases the normally aerated lung volume compared to pressure support ventilation [108]. By contrast, a latter study failed to identify any differences between airway pressure release ventilation and pressure support ventilation from admission to day 7 [109].

### **Acute heart failure**

Practical issues limit the application of CT in the acute phase for the diagnosis of acute cardiogenic pulmonary oedema. In a retrospective study, CT markers for acute pulmonary oedema (*i.e.* engorged peripheral pulmonary vessels, thickening of inter- and intra-lobular septa, ground glass opacities and consolidations) were compared with transpulmonary thermodilution technique variables [110]. The authors concluded that haemodynamic parameters obtained with transpulmonary thermodilution cannot be accurately estimated by CT. In a small study in ARDS patients, a good correlation was found between transpulmonary thermodilution and CT markers for pulmonary oedema [111]. Patients with acute pulmonary oedema presented with a similar amount of ground glass attenuation and a lower amount of airspace consolidation [112].

### **Pneumonia**

CT is more sensitive than CXR in detecting pulmonary infiltrates in patients with clinical suspicion of pneumonia [113, 114]. Similarly, in patients admitted to the emergency department with clinically suspected community-acquired pneumonia, CT modified the likelihood of diagnosing community-acquired pneumonia in 58% of cases [115].

In addition, CT can also provide a detailed morphological description of patients with ventilator-associated pneumonia. CT scans of a group of patients with ventilator-associated pneumonia at diagnosis

and at day 7 of antimicrobial therapy were characterised by the presence of intraparenchymal and subpleural rounded CT attenuations disseminated within the upper and lower lobes, with consolidations of the lower and upper lobes [54]. Patients who responded successfully to antimicrobial therapy showed predominant disappearance of the rounded opacities, whereas antibiotic failures correlated with new onset of rounded opacities within the lungs. A significant correlation was found between chest CT diagnosis of pneumonia and electronic nose sensor of the expired gases, a new promising adjunct tool for the diagnosis of pneumonia [116].

### **COPD**

Patients with severe acute exacerbation of COPD, due to infection or cardiac failure, frequently require mechanical ventilation with PEEP to improve oxygenation and to reduce the work of breathing. However, the increase in PEEP is associated with an increase in lung volume with possible risks of overinflation [117].

In addition, COPD patients are at increased risk of developing pulmonary thromboemboli. During a 5-year follow-up from an acute exacerbation of COPD, 17% of patients developed pulmonary embolism; the ICU length of stay and mortality were significantly higher in patients with pulmonary embolism [118].

### **Pneumothorax**

CT is commonly used for the diagnosis of pneumothorax. It is known that supine CXR is not sensitive for the diagnosis of pneumothorax in non-ICU patients [119, 120].

Very few studies have compared conventional CXR with CT in ICU patients. However, in a prospective study of 42 ICU patients, none of the eight pneumothoraces diagnosed by CT were seen with CXR [121].

### **Pleural effusion**

The quantitative computation of pleural effusion with whole chest CT has been demonstrated to significantly relate to the amount of pleural effusion computed with LU using a multiplanar ultrasound approach considering the cephalocaudal extension and the area measured at mid length [122].

### **PET**

The studies on PET used to prepare this statement are listed in table 4. PET provides a functional examination, detecting the presence of a radioactive tracer that is usually administered to patients linked to a biological molecule. One of the most common tracers is [18F]-2-fluoro-2-deoxy-D-glucose (18FDG). In the presence of an inflammatory status there is an increase in cellular metabolism and glucose consumption, mainly linked to neutrophilic activity.

### **ARDS**

ARDS lung is characterised by an increase in pulmonary vascular permeability in addition to abnormalities in gas exchange [1]. Pulmonary vascular permeability can be assessed by the pulmonary transcapillary escape rate for transferrin with PET (PTCER), which evaluates the protein flux between the pulmonary intravascular and extravascular compartments. ARDS and pneumonia patients have been found to present with a significantly higher PTCER than heart failure patients and healthy subjects [123]. In a group of pneumonia patients, PTCER was also higher in the regions contralateral to focal pneumonia [123]. ARDS in the early phases has been found to have a higher PTCER compared to the late phases [124], which is still higher than that of healthy subjects [124].

The current lung ARDS model, extensively explained by CT, indicates that regions of normal aeration coexist with poorly and non-aerated lung regions, and that lung densities are mainly located in the dependent lung regions [125]. Similarly, PET shows a significant increase in lung density in dorsal compared to ventral lung regions, with a higher amount of the same lung regions compared to healthy subjects [126]. Surprisingly, no difference has been found in the PTCER distribution between the dorsal and ventral lung regions. Despite a lack of difference between the ventral and dorsal regions, PTCER was not uniformly distributed in ARDS patients, thereby suggesting a possible blood-borne delivery of injurious agents to the lung [126].

Combining PET and CT with 18FDG it is possible to assess the distribution and magnitude of inflammation within the lung. Different approaches have been proposed, such as the simple static model that measures the standardised uptake volume, dynamic models that analyse the spectral analysis filter, and the Patlak analysis. In a comparison of the static and dynamic models in ARDS patients, the dynamic model provided a better description of lung inflammation [127]. In ARDS patients, the metabolic activity of the lungs was significantly higher than in healthy subjects, and did not correlate with the mean lung density or with the relative weight of either non-aerated or normally aerated tissue [128]. The inflammation activity negatively correlated with oxygenation levels. In the normally aerated tissue the



TABLE 4 Studies included on PET

Disease	Reference	First author	Aim	Subjects	Study design	Main results
ARDS	[123]	Kaplan JD	To measure pulmonary vascular permeability	43	Prospective	ARDS and pneumonia had higher PTCER
ARDS	[124]	Calandrino FS	To measure pulmonary vascular permeability	27	Prospective	Early <i>versus</i> late ARDS had higher PTCER
ARDS	[125]	Sandiford P	To measure regional distribution of vascular permeability	8	Observational	No difference in the distribution of PTCER
ARDS	[126]	Grecchi E	To investigate PET static and dynamic model analysis	11	Observational	Dynamic model better described lung inflammation
ARDS	[127]	Bellani G	To investigate inflammation distribution	10	Observational	Lung inflammation was diffusely distributed within the lung
ARDS	[128]	Bellani G	To assess gas volume changes and metabolic activity	13	Observational	No difference in lung inflammation between recruited-derecruited and collapsed regions
ARDS	[129]	Cressoni M	To determine size and location of lung inhomogeneity and inflammation	20	Observational	Different regional distribution of inhomogeneity and inflammation
AHF	[130]	Schuster DP	To assess perfusion distribution	21	Observational	Similar pulmonary blood flow among the groups
Pneumonia	[131]	Chen DL	To investigate the relationship between lung inflammation and lung function	27	Observational	Patients with cystic fibrosis had higher inflammation compared to healthy subjects
Pneumonia	[132]	Nusair S	To assess possible use of PET in interstitial lung disease	21	Observational	No difference in tracer uptake between patients with different interstitial lung diseases
Pneumonia	[133]	Umeda Y	To assess the degree of inflammation and disease progression	50	Observational	Possible use in analysis of disease progression and response to therapy
COPD	[134]	Vidal Melo MF	To assess ventilation distribution in COPD	12	Observational	High heterogeneity of ventilation distribution in COPD
Pleural effusion	[135]	Nakajima R	To discriminate benign from malignant pleural effusion	79	Retrospective	Good accuracy in discriminating benign from malignant pleural effusion
Pleural effusion	[136]	Duysink BC	To discriminate benign from malignant pleural effusion	36	Retrospective	Good accuracy in discriminating benign from malignant pleural effusion

PET: positron emission tomography; ARDS: acute respiratory distress syndrome; PTCER: pulmonary transcapillary escape rate; AHF: acute heart failure; COPD: chronic obstructive pulmonary disease.

metabolic activity was significantly higher, up to seven times, than that of healthy subjects. Additionally, lung inflammation was very differently distributed considering the distribution of inflation (from non-inflated to well-inflated regions) [128].

The same authors analysed the relationship between gas volume changes induced by tidal ventilation, from end expiration to end inspiration, and pulmonary inflammation [129]. The lung regions undergoing intra-tidal recruitment and de-recruitment during tidal breathing had similar lung inflammation to the collapsed ones. Airway pressure positively correlated with lung inflammation [129].

Owing to the greater distribution of lung oedema in the dorsal regions, greater lung inhomogeneity of lung parenchyma may be present along the sternum–vertebral axis. Concerning the distribution of lung inhomogeneity and inflammation within the lung, the amount of lung inflammation and inhomogeneity has been shown to increase from mild to severe ARDS [130]. In that study, the homogeneous lung compartment with normal PET signal was mainly composed of well-inflated tissue and was located in the ventral regions. By contrast, the inhomogeneous compartment with high PET signal was composed of non- or poorly inflated tissue and located in the dorsal regions. The homogeneous lung compartment with high PET signal comprised mixed lung aeration from non-inflated to well-inflated regions and was similarly distributed within the lung [130].

#### **Acute heart failure**

Pulmonary hypertension, which is frequent in ARDS patients, has been associated with pulmonary vasoconstriction in response to hypoxia, which could redistribute pulmonary blood flow within the sick lung. The ventral to dorsal regional distribution of pulmonary blood flow has been analysed in a group of patients with pulmonary lung oedema and in healthy subjects [131]. Although the amount of lung water concentration was significantly higher in ARDS and cardiogenic pulmonary oedema, the regional distribution of pulmonary blood flow was similar among ARDS and healthy subjects [131].

#### **Pneumonia**

By analysing the uptake of tracer by activated inflammatory cells, PET can provide a quantitative assessment of lung infection and assess the response to therapy. The pulmonary transcappillary escape rate has proved to be significantly higher in areas of radiographic infiltrates in patients with pneumonia compared to normal subjects [123].

Cystic fibrosis patients are characterised by persistent lung inflammation with high levels of neutrophil activation, translating clinically into frequent episodes of lung infections. In patients with cystic fibrosis, PET showed a higher uptake of 18FDG compared to healthy subjects, and this feature positively correlated with the number of neutrophils in the bronchoalveolar lavage fluid [132].

PET has also been proposed in the diagnosis of interstitial lung diseases. In a small group of patients with diffuse interstitial lung disease, the tracer uptake was not different in patients with and without idiopathic pulmonary fibrosis (IPF) [133]. By contrast, in cryptogenic organising pneumonia the tracer uptake was significantly higher compared to IPF and nonspecific interstitial pneumonia (NSIP), while similar levels were detected between IPF and NSIP [134].

#### **COPD**

COPD patients are characterised by significant alterations in the distribution of ventilation and perfusion. By applying an innovative PET analysis, VIDAL *et al.* [135] analysed ventilation and perfusion within the lung imaging resolution unit (voxel). There was greater perfusion heterogeneity in COPD, compared to in healthy subjects, with no dorsoventral ventilation gradient.

#### **Pleural effusion**

Owing to the intrinsic differences in glucose metabolism between normal and tumour cells, PET can distinguish benign from malignant pleural effusions. Malignant pleural effusions have shown a significantly higher glucose uptake compared to benign effusions, with the technique having good sensitivity and a relatively low specificity in detecting malignant pleural effusions (93% and 68%, respectively) [136, 137].

#### **EIT**

EIT uses multiple electrodes applied to the external chest surface and the application of a low voltage current to measure both absolute and relative variations of body impedance. A two-dimensional image, of approximately 10 cm, is created with good correlation to intrapulmonary lung gas volume and intrathoracic blood volume. EIT applications range from monitoring mechanical ventilation (PEEP selection, lung recruitability, distribution of ventilation) to estimating lung perfusion and pulmonary function [138–140].

Based on our criteria selection, no articles were found on this topic.

### Conclusions and need for future research

Patients with acute respiratory failure due to different lung causes and high mortality risk require numerous lung studies. As a first level examination, CXR, despite its intrinsic limitations and low accuracy, may still play a relevant role. CT remains the gold standard, but it requires patient transportation and use of radiation, which preclude extensive use especially within the same patient. LU, after proper physician training, is able to provide greater accuracy than CXR, similar to that of CT. EIT is gaining a more clinical role after many years as a research tool, while PET has a minimal role in the acute phase of respiratory failure.

As bedside lung imaging techniques, LU and EIT will become more frequently used in patients with acute respiratory failure. Future studies will assess if the information provided will improve clinical management and outcome. Regarding CT, the possibility of dose reduction protocols and safer patient transport to the radiology department will extend its application. There is a clinical need for studies combining different methods for diagnosis and patient monitoring.

Conflict of interest: D. Chiumello has nothing to disclose. G.F. Sferrazza Papa has nothing to disclose. A. Artigas reports grants from Grifols, Fisher & Paykel, Fundacion Areces and Instituto Carlos III, outside the submitted work. B. Bouhemad has nothing to disclose. A. Grgic reports personal fees from MSD, Boehringer Ingelheim, Roche and Bayer Vital, outside the submitted work. L. Heunks reports personal fees for travel and lecturing from Maquet critical care, and grants from Ventfree and Orionpharma, outside the submitted work. K. Markstaller has nothing to disclose. G.M. Pellegrino has nothing to disclose. L. Pisani has nothing to disclose. D. Rigau works as a methodologist for the ERS. M.J. Schultz has nothing to disclose. G. Sotgiu has nothing to disclose. P. Spieth has nothing to disclose. M. Zompatori has nothing to disclose. P. Navalesi has nothing to disclose.

### References

- 1 Ranieri VM, Rubenfeld GD, Thompson BT, *et al.* Acute respiratory distress syndrome: the Berlin Definition. *JAMA* 2012; 307: 2526–2533.
- 2 Rubenfeld GD, Caldwell E, Granton J, *et al.* Interobserver variability in applying a radiographic definition for ARDS. *Chest* 1999; 116: 1347–1353.
- 3 Figueroa-Casas JB, Brunner N, Dwivedi AK, *et al.* Accuracy of the chest radiograph to identify bilateral pulmonary infiltrates consistent with the diagnosis of acute respiratory distress syndrome using computed tomography as reference standard. *J Crit Care* 2013; 28: 352–357.
- 4 Fröhlich S, Murphy N, Doolan A, *et al.* Acute respiratory distress syndrome: underrecognition by clinicians. *J Crit Care* 2013; 28: 663–668.
- 5 Peng J-M, Qian C-Y, Yu X-Y, *et al.* Does training improve diagnostic accuracy and inter-rater agreement in applying the Berlin radiographic definition of acute respiratory distress syndrome? A multicenter prospective study. *Crit Care* 2017; 21: 12.
- 6 Goddard SL, Rubenfeld GD, Manoharan V, *et al.* The Randomized Educational Acute Respiratory Distress Syndrome Diagnosis study: a trial to improve the radiographic diagnosis of acute respiratory distress syndrome. *Crit Care Med* 2018; 46: 743–748.
- 7 Halperin BD, Feeley TW, Mihm FG, *et al.* Evaluation of the portable chest roentgenogram for quantitating extravascular lung water in critically ill adults. *Chest* 1985; 88: 649–652.
- 8 Martin GS, Ely EW, Carroll FE, *et al.* Findings on the portable chest radiograph correlate with fluid balance in critically ill patients. *Chest* 2002; 122: 2087–2095.
- 9 Thomason JW, Ely EW, Chiles C, *et al.* Appraising pulmonary edema using supine chest roentgenograms in ventilated patients. *Am J Respir Crit Care Med* 1998; 157: 1600–1608.
- 10 Farshidpanah S, Klein W, Matus M, *et al.* Validation of the vascular pedicle width as a diagnostic aid in critically ill patients with pulmonary oedema by novice non-radiology physicians-in-training. *Anaesth Intensive Care* 2014; 42: 321–329.
- 11 Lefcoe MS, Fox GA, Leasa DJ, *et al.* Accuracy of portable chest radiography in the critical care setting. Diagnosis of pneumonia based on quantitative cultures obtained from protected brush catheter. *Chest* 1994; 105: 885–887.
- 12 Butler KL, Sinclair KE, Henderson VJ, *et al.* The chest radiograph in critically ill surgical patients is inaccurate in predicting ventilator-associated pneumonia. *Am Surg* 1999; 65: 805–810.
- 13 Moine P, Vercken JB, Chevret S, *et al.* Severe community-acquired pneumococcal pneumonia. The French Study Group of Community-Acquired Pneumonia in ICU. *Scand J Infect Dis* 1995; 27: 201–206.
- 14 Schulman CI, Cohn SM, Blackburn L, *et al.* How long should you wait for a chest radiograph after placing a chest tube on water seal? A prospective study. *J Trauma* 2005; 59: 92–95.
- 15 Pizano LR, Houghton DE, Cohn SM, *et al.* When should a chest radiograph be obtained after chest tube removal in mechanically ventilated patients? A prospective study. *J Trauma* 2002; 53: 1073–1077.
- 16 Emamian SA, Kaasbol MA, Olsen JF, *et al.* Accuracy of the diagnosis of pleural effusion on supine chest X-ray. *Eur Radiol* 1997; 7: 57–60.
- 17 Brixey AG, Luo Y, Skouras V, *et al.* The efficacy of chest radiographs in detecting parapneumonic effusions. *Respirology* 2011; 16: 1000–1004.
- 18 Volpicelli G, Elbarbary M, Blaivas M, *et al.* International evidence-based recommendations for point-of-care lung ultrasound. *Intensive Care Med* 2012; 38: 577–591.
- 19 Copetti R, Soldati G, Copetti P. Chest sonography: a useful tool to differentiate acute cardiogenic pulmonary edema from acute respiratory distress syndrome. *Cardiovasc Ultrasound* 2008; 6: 16.

- 20 Sekiguchi H, Schenck LA, Horie R, *et al.* Critical care ultrasonography differentiates ARDS, pulmonary edema, and other causes in the early course of acute hypoxemic respiratory failure. *Chest* 2015; 148: 912–918.
- 21 Bass CM, Sajed DR, Adedipe AA, *et al.* Pulmonary ultrasound and pulse oximetry versus chest radiography and arterial blood gas analysis for the diagnosis of acute respiratory distress syndrome: a pilot study. *Crit Care* 2015; 19: 282.
- 22 Huang D, Ma H, Xiao Z, *et al.* Diagnostic value of cardiopulmonary ultrasound in elderly patients with acute respiratory distress syndrome. *BMC Pulm Med* 2018; 18: 136.
- 23 Riviello ED, Kiviri W, Twagirumugabe T, *et al.* Hospital incidence and outcomes of the acute respiratory distress syndrome using the Kigali modification of the Berlin definition. *Am J Respir Crit Care Med* 2016; 193: 52–59.
- 24 Zhao Z, Jiang L, Xi X, *et al.* Prognostic value of extravascular lung water assessed with lung ultrasound score by chest sonography in patients with acute respiratory distress syndrome. *BMC Pulm Med* 2015; 15: 98.
- 25 Tsubo T, Yatsu Y, Suzuki A, *et al.* Daily changes of the area of density in the dependent lung region - evaluation using transesophageal echocardiography. *Intensive Care Med* 2001; 27: 1881–1886.
- 26 Tsubo T, Sakai I, Suzuki A, *et al.* Density detection in dependent left lung region using transesophageal echocardiography. *Anesthesiology* 2001; 94: 793–798.
- 27 Tsubo T, Yatsu Y, Tanabe T, *et al.* Evaluation of density area in dorsal lung region during prone position using transesophageal echocardiography. *Crit Care Med* 2004; 32: 83–87.
- 28 Stefanidis K, Dimopoulos S, Tripodaki E-S, *et al.* Lung sonography and recruitment in patients with early acute respiratory distress syndrome: a pilot study. *Crit Care* 2011; 15: R185.
- 29 Bouhemad B, Brisson H, Le-Guen M, *et al.* Bedside ultrasound assessment of positive end-expiratory pressure-induced lung recruitment. *Am J Respir Crit Care Med* 2011; 183: 341–347.
- 30 Chiumello D, Mongodi S, Algieri I, *et al.* Assessment of lung aeration and recruitment by CT scan and ultrasound in acute respiratory distress syndrome patients. *Crit Care Med* 2018; 46: 1761–1768.
- 31 Enghard P, Rademacher S, Nee J, *et al.* Simplified lung ultrasound protocol shows excellent prediction of extravascular lung water in ventilated intensive care patients. *Crit Care* 2015; 19: 36.
- 32 Jambrik Z, Monti S, Coppola V, *et al.* Usefulness of ultrasound lung comets as a nonradiologic sign of extravascular lung water. *Am J Cardiol* 2004; 93: 1265–1270.
- 33 Volpicelli G, Skurzak S, Boero E, *et al.* Lung ultrasound predicts well extravascular lung water but is of limited usefulness in the prediction of wedge pressure. *Anesthesiology* 2014; 121: 320–327.
- 34 Mallamaci F, Benedetto FA, Tripepi R, *et al.* Detection of pulmonary congestion by chest ultrasound in dialysis patients. *JACC Cardiovasc Imaging* 2010; 3: 586–594.
- 35 Noble VE, Murray AF, Capp R, *et al.* Ultrasound assessment for extravascular lung water in patients undergoing hemodialysis. Time course for resolution. *Chest* 2009; 135: 1433–1439.
- 36 Lichtenstein DA, Mezière GA, Lagoueyte J-F, *et al.* A-lines and B-lines: lung ultrasound as a bedside tool for predicting pulmonary artery occlusion pressure in the critically ill. *Chest* 2009; 136: 1014–1020.
- 37 Laursen CB, Hänselmann A, Posth S, *et al.* Prehospital lung ultrasound for the diagnosis of cardiogenic pulmonary oedema: a pilot study. *Scand J Trauma Resusc Emerg Med* 2016; 24: 96.
- 38 Cortellaro F, Ceriani E, Spinelli M, *et al.* Lung ultrasound for monitoring cardiogenic pulmonary edema. *Intern Emerg Med* 2017; 12: 1011–1017.
- 39 Martindale JL, Secko M, Kilpatrick JF, *et al.* Serial sonographic assessment of pulmonary edema in patients with hypertensive acute heart failure. *J Ultrasound Med* 2018; 37: 337–345.
- 40 Lichtenstein D, Mézière G, Biderman P, *et al.* The comet-tail artifact. An ultrasound sign of alveolar-interstitial syndrome. *Am J Respir Crit Care Med* 1997; 156: 1640–1646.
- 41 Silva S, Biendel C, Ruiz J, *et al.* Usefulness of cardiothoracic chest ultrasound in the management of acute respiratory failure in critical care practice. *Chest* 2013; 144: 859–865.
- 42 Yang PC, Luh KT, Chang DB, *et al.* Ultrasonographic evaluation of pulmonary consolidation. *Am Rev Respir Dis* 1992; 146: 757–762.
- 43 Testa A, Soldati G, Copetti R, *et al.* Early recognition of the 2009 pandemic influenza A (H1N1) pneumonia by chest ultrasound. *Crit Care* 2012; 16: R30.
- 44 Reissig A, Kroegel C. Sonographic diagnosis and follow-up of pneumonia: a prospective study. *Respir Int Rev Thorac Dis* 2007; 74: 537–547.
- 45 Parlamento S, Copetti R, Di Bartolomeo S. Evaluation of lung ultrasound for the diagnosis of pneumonia in the ED. *Am J Emerg Med* 2009; 27: 379–384.
- 46 Sperandeo M, Carnevale V, Muscarella S, *et al.* Clinical application of transthoracic ultrasonography in inpatients with pneumonia. *Eur J Clin Invest* 2011; 41: 1–7.
- 47 Cortellaro F, Colombo S, Coen D, *et al.* Lung ultrasound is an accurate diagnostic tool for the diagnosis of pneumonia in the emergency department. *Emerg Med J* 2012; 29: 19–23.
- 48 Reissig A, Copetti R, Mathis G, *et al.* Lung ultrasound in the diagnosis and follow-up of community-acquired pneumonia: a prospective, multicenter, diagnostic accuracy study. *Chest* 2012; 142: 965–972.
- 49 Bourcier J-E, Paquet J, Seinger M, *et al.* Performance comparison of lung ultrasound and chest X-ray for the diagnosis of pneumonia in the ED. *Am J Emerg Med* 2014; 32: 115–118.
- 50 Corradi F, Brusasco C, Garlaschi A, *et al.* Quantitative analysis of lung ultrasonography for the detection of community-acquired pneumonia: a pilot study. *Biomed Res Int* 2015; 2015: 868707.
- 51 Liu X, Lian R, Tao Y, *et al.* Lung ultrasonography: an effective way to diagnose community-acquired pneumonia. *Emerg Med J* 2015; 32: 433–438.
- 52 Pagano A, Numis FG, Visone G, *et al.* Lung ultrasound for diagnosis of pneumonia in emergency department. *Intern Emerg Med* 2015; 10: 851–854.
- 53 Lichtenstein D, Mezière G, Seitz J. The dynamic air bronchogram. A lung ultrasound sign of alveolar consolidation ruling out atelectasis. *Chest* 2009; 135: 1421–1425.
- 54 Bouhemad B, Liu Z-H, Arbelot C, *et al.* Ultrasound assessment of antibiotic-induced pulmonary reaeration in ventilator-associated pneumonia. *Crit Care Med* 2010; 38: 84–92.
- 55 Mongodi S, Via G, Girard M, *et al.* Lung ultrasound for early diagnosis of ventilator-associated pneumonia. *Chest* 2016; 149: 969–980.

- 56 Lichtenstein D, Mezière G, Biderman P, *et al.* The lung point: an ultrasound sign specific to pneumothorax. *Intensive Care Med* 2000; 26: 1434–1440.
- 57 Volpicelli G, Boero E, Sverzellati N, *et al.* Semi-quantification of pneumothorax volume by lung ultrasound. *Intensive Care Med* 2014; 40: 1460–1467.
- 58 Dulchavsky SA, Schwarz KL, Kirkpatrick AW, *et al.* Prospective evaluation of thoracic ultrasound in the detection of pneumothorax. *J Trauma* 2001; 50: 201–205.
- 59 Kirkpatrick AW, Sirois M, Laupland KB, *et al.* Hand-held thoracic sonography for detecting post-traumatic pneumothoraces: the Extended Focused Assessment with Sonography for Trauma (EFAST). *J Trauma* 2004; 57: 288–295.
- 60 Weekes AJ, Keller SM, Efune B, *et al.* Prospective comparison of ultrasound and CXR for confirmation of central vascular catheter placement. *Emerg Med J* 2016; 33: 176–180.
- 61 Vezzani A, Brusasco C, Palermo S, *et al.* Ultrasound localization of central vein catheter and detection of postprocedural pneumothorax: an alternative to chest radiography. *Crit Care Med* 2010; 38: 533–538.
- 62 Maury E, Guglielminotti J, Alzieu M, *et al.* Ultrasonic examination: an alternative to chest radiography after central venous catheter insertion? *Am J Respir Crit Care Med* 2001; 164: 403–405.
- 63 Saucier S, Motyka C, Killu K. Ultrasonography versus chest radiography after chest tube removal for the detection of pneumothorax. *AACN Adv Crit Care* 2010; 21: 34–38.
- 64 Lichtenstein D, Hulot JS, Rabiller A, *et al.* Feasibility and safety of ultrasound-aided thoracentesis in mechanically ventilated patients. *Intensive Care Med* 1999; 25: 955–958.
- 65 Vignon P, Chastagner C, Berkane V, *et al.* Quantitative assessment of pleural effusion in critically ill patients by means of ultrasonography. *Crit Care Med* 2005; 33: 1757–1763.
- 66 Rozycki GS, Pennington SD, Feliciano DV. Surgeon-performed ultrasound in the critical care setting: its use as an extension of the physical examination to detect pleural effusion. *J Trauma* 2001; 50: 636–642.
- 67 Rocco M, Carbone I, Morelli A, *et al.* Diagnostic accuracy of bedside ultrasonography in the ICU: feasibility of detecting pulmonary effusion and lung contusion in patients on respiratory support after severe blunt thoracic trauma. *Acta Anaesthesiol Scand* 2008; 52: 776–784.
- 68 Gallard E, Redonnet J-P, Bourcier J-E, *et al.* Diagnostic performance of cardiopulmonary ultrasound performed by the emergency physician in the management of acute dyspnea. *Am J Emerg Med* 2015; 33: 352–358.
- 69 Yu CJ, Yang PC, Chang DB, *et al.* Diagnostic and therapeutic use of chest sonography: value in critically ill patients. *AJR Am J Roentgenol* 1992; 159: 695–701.
- 70 Mayo PH, Goltz HR, Tafreshi M, *et al.* Safety of ultrasound-guided thoracentesis in patients receiving mechanical ventilation. *Chest* 2004; 125: 1059–1062.
- 71 Schleder S, Dornia C, Poschenrieder F, *et al.* Bedside diagnosis of pleural effusion with a latest generation hand-carried ultrasound device in intensive care patients. *Acta Radiol* 2012; 53: 556–560.
- 72 Awerbuch E, Benavides M, Gershengorn HB. The impact of computed tomography of the chest on the management of patients in a medical intensive care unit. *J Intensive Care Med* 2015; 30: 505–511.
- 73 Owens CM, Evans TW, Keogh BF, *et al.* Computed tomography in established adult respiratory distress syndrome. Correlation with lung injury score. *Chest* 1994; 106: 1815–1821.
- 74 Bombino M, Gattinoni L, Pesenti A, *et al.* The value of portable chest roentgenography in adult respiratory distress syndrome. Comparison with computed tomography. *Chest* 1991; 100: 762–769.
- 75 Puybasset L, Gusman P, Muller JC, *et al.* Regional distribution of gas and tissue in acute respiratory distress syndrome. III. Consequences for the effects of positive end-expiratory pressure. *Intensive Care Med* 2000; 26: 1215–1227.
- 76 Patroniti N, Bellani G, Muggioni E, *et al.* Measurement of pulmonary edema in patients with acute respiratory distress syndrome. *Crit Care Med* 2005; 33: 2547–2554.
- 77 Patroniti N, Bellani G, Manfio A, *et al.* Lung volume in mechanically ventilated patients: measurement by simplified helium dilution compared to quantitative CT scan. *Intensive Care Med* 2004; 30: 282–289.
- 78 Lu Q, Malbouisson LM, Mourgeon E, *et al.* Assessment of PEEP-induced reopening of collapsed lung regions in acute lung injury: are one or three CT sections representative of the entire lung? *Intensive Care Med* 2001; 27: 1504–1510.
- 79 Vieira SRR, Nieszkowska A, Lu Q, *et al.* Low spatial resolution computed tomography underestimates lung overinflation resulting from positive pressure ventilation. *Crit Care Med* 2005; 33: 741–749.
- 80 Reske AW, Costa ELV, Reske AP, *et al.* Bedside estimation of nonaerated lung tissue using blood gas analysis. *Crit Care Med* 2013; 41: 732–743.
- 81 Caironi P, Carlesso E, Cressoni M, *et al.* Lung recruitability is better estimated according to the Berlin definition of acute respiratory distress syndrome at standard 5 cm H<sub>2</sub>O rather than higher positive end-expiratory pressure: a retrospective cohort study. *Crit Care Med* 2015; 43: 781–790.
- 82 Rouby JJ, Puybasset L, Cluzel P, *et al.* Regional distribution of gas and tissue in acute respiratory distress syndrome. II. Physiological correlations and definition of an ARDS severity score. *Intensive Care Med* 2000; 26: 1046–1056.
- 83 Stelter L, Steffen I, Pinkernelle JG, *et al.* Computed tomography findings in septic patients with acute respiratory distress syndrome: correlation with survival and pulmonary versus extrapulmonary septic focus. *J Comput Assist Tomogr* 2013; 37: 602–609.
- 84 Lazoura O, Parthipun AA, Robertson BJ, *et al.* Acute respiratory distress syndrome related to influenza A H1N1 infection: correlation of pulmonary computed tomography findings to extracorporeal membrane oxygenation treatment and clinical outcome. *J Crit Care* 2012; 27: 602–608.
- 85 Simon M, Braune S, Laqmani A, *et al.* Value of computed tomography of the chest in subjects with ARDS: a retrospective observational study. *Respir Care* 2016; 61: 316–323.
- 86 Chiumello D, Langer T, Vecchi V, *et al.* Low-dose chest computed tomography for quantitative and visual anatomical analysis in patients with acute respiratory distress syndrome. *Intensive Care Med* 2014; 40: 691–699.
- 87 Klapsing P, Herrmann P, Quintel M, *et al.* Automatic quantitative computed tomography segmentation and analysis of aerated lung volumes in acute respiratory distress syndrome—A comparative diagnostic study. *J Crit Care* 2017; 42: 184–191.

- 88 Miller PR, Croce MA, Bee TK, *et al.* ARDS after pulmonary contusion: accurate measurement of contusion volume identifies high-risk patients. *J Trauma* 2001; 51: 223–230.
- 89 Reske AW, Reske AP, Heine T, *et al.* Computed tomographic assessment of lung weights in trauma patients with early posttraumatic lung dysfunction. *Crit Care* 2011; 15: R71.
- 90 Chiumello D, Marino A, Cressoni M, *et al.* Pleural effusion in patients with acute lung injury: a CT scan study. *Crit Care Med* 2013; 41: 935–944.
- 91 Gattinoni L, Bombino M, Pelosi P, *et al.* Lung structure and function in different stages of severe adult respiratory distress syndrome. *JAMA* 1994; 271: 1772–1779.
- 92 Treggiari MM, Romand J-A, Martin J-B, *et al.* Air cysts and bronchiectasis prevail in nondependent areas in severe acute respiratory distress syndrome: a computed tomographic study of ventilator-associated changes. *Crit Care Med* 2002; 30: 1747–1752.
- 93 Burnham EL, Hyzy RC, Paine R, *et al.* Chest CT features are associated with poorer quality of life in acute lung injury survivors. *Crit Care Med* 2013; 41: 445–456.
- 94 Nöbauer-Huhmann IM, Eibenberger K, Schaefer-Prokop C, *et al.* Changes in lung parenchyma after acute respiratory distress syndrome (ARDS): assessment with high-resolution computed tomography. *Eur Radiol* 2001; 11: 2436–2443.
- 95 Masclans JR, Roca O, Muñoz X, *et al.* Quality of life, pulmonary function, and tomographic scan abnormalities after ARDS. *Chest* 2011; 139: 1340–1346.
- 96 Kim SJ, Oh BJ, Lee JS, *et al.* Recovery from lung injury in survivors of acute respiratory distress syndrome: difference between pulmonary and extrapulmonary subtypes. *Intensive Care Med* 2004; 30: 1960–1963.
- 97 Cressoni M, Chiumello D, Carlesso E, *et al.* Compressive forces and computed tomography-derived positive end-expiratory pressure in acute respiratory distress syndrome. *Anesthesiology* 2014; 121: 572–581.
- 98 Puybasset L, Cluzel P, Gusman P, *et al.* Regional distribution of gas and tissue in acute respiratory distress syndrome. I. Consequences for lung morphology. *Intensive Care Med* 2000; 26: 857–869.
- 99 Constantin J-M, Grasso S, Chanques G, *et al.* Lung morphology predicts response to recruitment maneuver in patients with acute respiratory distress syndrome. *Crit Care Med* 2010; 38: 1108–1117.
- 100 Chiumello D, Colombo A, Algieri I, *et al.* Effect of body mass index in acute respiratory distress syndrome. *Br J Anaesth* 2016; 116: 113–121.
- 101 Cressoni M, Chiumello D, Algieri I, *et al.* Opening pressures and atelectrauma in acute respiratory distress syndrome. *Intensive Care Med* 2017; 43: 603–611.
- 102 Cressoni M, Cadringer P, Chiurazzi C, *et al.* Lung inhomogeneity in patients with acute respiratory distress syndrome. *Am J Respir Crit Care Med* 2014; 189: 149–158.
- 103 Chiumello D, Cressoni M, Carlesso E, *et al.* Bedside selection of positive end-expiratory pressure in mild, moderate, and severe acute respiratory distress syndrome. *Crit Care Med* 2014; 42: 252–264.
- 104 Constantin J-M, Jaber S, Futier E, *et al.* Respiratory effects of different recruitment maneuvers in acute respiratory distress syndrome. *Crit Care* 2008; 12: R50.
- 105 Galiatsou E, Kostanti E, Svarna E, *et al.* Prone position augments recruitment and prevents alveolar overinflation in acute lung injury. *Am J Respir Crit Care Med* 2006; 174: 187–197.
- 106 Lu Q, Zhang M, Girardi C, *et al.* Computed tomography assessment of exogenous surfactant-induced lung reaeration in patients with acute lung injury. *Crit Care* 2010; 14: R135.
- 107 Lu Q, Constantin J-M, Nieszkowska A, *et al.* Measurement of alveolar derecruitment in patients with acute lung injury: computerized tomography versus pressure-volume curve. *Crit Care* 2006; 10: R95.
- 108 Yoshida T, Rinka H, Kaji A, *et al.* The impact of spontaneous ventilation on distribution of lung aeration in patients with acute respiratory distress syndrome: airway pressure release ventilation versus pressure support ventilation. *Anesth Analg* 2009; 109: 1892–1900.
- 109 Varpula T, Valta P, Markkola A, *et al.* The effects of ventilatory mode on lung aeration assessed with computer tomography: a randomized controlled study. *J Intensive Care Med* 2009; 24: 122–130.
- 110 Saugel B, Holzapfel K, Stollfuss J, *et al.* Computed tomography to estimate cardiac preload and extravascular lung water. A retrospective analysis in critically ill patients. *Scand J Trauma Resusc Emerg Med* 2011; 19: 31.
- 111 Zhang F, Li C, Zhang J, *et al.* Comparison of quantitative computed tomography analysis and single-indicator thermodilution to measure pulmonary edema in patients with acute respiratory distress syndrome. *Biomed Eng Online* 2014; 13: 30.
- 112 Vergani G, Cressoni M, Crimella F, *et al.* A morphological and quantitative analysis of lung CT scan in patients with acute respiratory distress syndrome and in cardiogenic pulmonary edema. *J Intensive Care Med* 2017; in press [DOI: 10.1177/0885066617743477].
- 113 Syrjälä H, Broas M, Suramo I, *et al.* High-resolution computed tomography for the diagnosis of community-acquired pneumonia. *Clin Infect Dis* 1998; 27: 358–363.
- 114 Gruden JF, Huang L, Turner J, *et al.* High-resolution CT in the evaluation of clinically suspected *Pneumocystis carinii* pneumonia in AIDS patients with normal, equivocal, or nonspecific radiographic findings. *AJR Am J Roentgenol* 1997; 169: 967–975.
- 115 Claessens Y-E, Debray M-P, Tubach F, *et al.* Early chest computed tomography scan to assist diagnosis and guide treatment decision for suspected community-acquired pneumonia. *Am J Respir Crit Care Med* 2015; 192: 974–982.
- 116 Hockstein NG, Thaler ER, Torigian D, *et al.* Diagnosis of pneumonia with an electronic nose: correlation of vapor signature with chest computed tomography scan findings. *Laryngoscope* 2004; 114: 1701–1705.
- 117 Nieszkowska A, Lu Q, Vieira S, *et al.* Incidence and regional distribution of lung overinflation during mechanical ventilation with positive end-expiratory pressure. *Crit Care Med* 2004; 32: 1496–1503.
- 118 Bahloul M, Chaari A, Tounsi A, *et al.* Incidence and impact outcome of pulmonary embolism in critically ill patients with severe exacerbation of chronic obstructive pulmonary diseases. *Clin Respir J* 2015; 9: 270–277.
- 119 Lichtenstein DA, Mezière G, Lascols N, *et al.* Ultrasound diagnosis of occult pneumothorax. *Crit Care Med* 2005; 33: 1231–1238.
- 120 Soldati G, Testa A, Sher S, *et al.* Occult traumatic pneumothorax: diagnostic accuracy of lung ultrasonography in the emergency department. *Chest* 2008; 133: 204–211.
- 121 Xirouchaki N, Magkanas E, Vaporidi K, *et al.* Lung ultrasound in critically ill patients: comparison with bedside chest radiography. *Intensive Care Med* 2011; 37: 1488–1493.

- 122 Remérand F, Dellamonica J, Mao Z, *et al.* Multiplane ultrasound approach to quantify pleural effusion at the bedside. *Intensive Care Med* 2010; 36: 656–664.
- 123 Kaplan JD, Calandrino FS, Schuster DP. A positron emission tomographic comparison of pulmonary vascular permeability during the adult respiratory distress syndrome and pneumonia. *Am Rev Respir Dis* 1991; 143: 150–154.
- 124 Calandrino FS, Anderson DJ, Mintun MA, *et al.* Pulmonary vascular permeability during the adult respiratory distress syndrome: a positron emission tomographic study. *Am Rev Respir Dis* 1988; 138: 421–428.
- 125 Gattinoni L, Caironi P, Pelosi P, *et al.* What has computed tomography taught us about the acute respiratory distress syndrome? *Am J Respir Crit Care Med* 2001; 164: 1701–1711.
- 126 Sandiford P, Province MA, Schuster DP. Distribution of regional density and vascular permeability in the adult respiratory distress syndrome. *Am J Respir Crit Care Med* 1995; 151: 737–742.
- 127 Grecchi E, Veronese M, Moresco RM, *et al.* Quantification of dynamic [18F]FDG PET studies in acute lung injury. *Mol Imaging Biol* 2016; 18: 143–152.
- 128 Bellani G, Messa C, Guerra L, *et al.* Lungs of patients with acute respiratory distress syndrome show diffuse inflammation in normally aerated regions: a [18F]-fluoro-2-deoxy-D-glucose PET/CT study. *Crit Care Med* 2009; 37: 2216–2222.
- 129 Bellani G, Guerra L, Musch G, *et al.* Lung regional metabolic activity and gas volume changes induced by tidal ventilation in patients with acute lung injury. *Am J Respir Crit Care Med* 2011; 183: 1193–1199.
- 130 Cressoni M, Chiumello D, Chiurazzi C, *et al.* Lung inhomogeneities, inflation and [18F]2-fluoro-2-deoxy-D-glucose uptake rate in acute respiratory distress syndrome. *Eur Respir J* 2016; 47: 233–242.
- 131 Schuster DP, Anderson C, Kozlowski J, *et al.* Regional pulmonary perfusion in patients with acute pulmonary edema. *J Nucl Med* 2002; 43: 863–870.
- 132 Chen DL, Ferkol TW, Mintun MA, *et al.* Quantifying pulmonary inflammation in cystic fibrosis with positron emission tomography. *Am J Respir Crit Care Med* 2006; 173: 1363–1369.
- 133 Nusair S, Rubinstein R, Freedman NM, *et al.* Positron emission tomography in interstitial lung disease. *Respirology* 2007; 12: 843–847.
- 134 Umeda Y, Demura Y, Ishizaki T, *et al.* Dual-time-point 18F-FDG PET imaging for diagnosis of disease type and disease activity in patients with idiopathic interstitial pneumonia. *Eur J Nucl Med Mol Imaging* 2009; 36: 1121–1130.
- 135 Vidal Melo MF, Winkler T, Harris RS, *et al.* Spatial heterogeneity of lung perfusion assessed with (13)N PET as a vascular biomarker in chronic obstructive pulmonary disease. *J Nucl Med* 2010; 51: 57–65.
- 136 Nakajima R, Abe K, Sakai S. Diagnostic ability of FDG-PET/CT in the detection of malignant pleural effusion. *Medicine (Baltimore)* 2015; 94: e1010.
- 137 Duysinx BC, Larock M-P, Nguyen D, *et al.* 18F-FDG PET imaging in assessing exudative pleural effusions. *Nucl Med Commun* 2006; 27: 971–976.
- 138 Frerichs I, Amato MBP, van Kaam AH, *et al.* Chest electrical impedance tomography examination, data analysis, terminology, clinical use and recommendations: consensus statement of the TRanslational EIT developmeNt stuDy group. *Thorax* 2017; 72: 83–93.
- 139 Walsh BK, Smallwood CD. Electrical impedance tomography during mechanical ventilation. *Respir Care* 2016; 61: 1417–1424.
- 140 Riera J, Riu PJ, Casan P, *et al.* Tomografía de impedancia eléctrica en la lesión pulmonar aguda [Electrical impedance tomography in acute lung injury]. *Med Intensiva* 2011; 35: 509–517.